

## A combination of ursodeoxycholic acid and *Allium sativum* prevents liver cirrhosis in cholestatic rats

Pratama Nurmalik Adhuri<sup>1,\*</sup> , Neni Susilaningsih<sup>2</sup> , Sigit Adi Prasetyo<sup>3</sup> , Nani Maharani<sup>4</sup> , Trilaksana Nugroho<sup>4</sup> 

<sup>1</sup>Biomedical Science Postgraduate Program, Faculty of Medicine, Diponegoro University, Semarang, Indonesia

<sup>2</sup>Department of Histology, Faculty of Medicine, Diponegoro University, Semarang, Indonesia

<sup>3</sup>Department of Digestive Surgery, Faculty of Medicine, Diponegoro University, Semarang, Indonesia

<sup>4</sup>Department of Pharmacology, Faculty of Medicine, Diponegoro University, Semarang, Indonesia

### \*Corresponding author

Pratama Nurmalik Adhuri  
Biomedical Science Postgraduate  
Program, Faculty of Medicine,  
Diponegoro University, Semarang,  
Indonesia.  
Email: [pratama.adhuri@gmail.com](mailto:pratama.adhuri@gmail.com)

### Academic editor

Md. Abdul Hannan, PhD  
Bangladesh Agricultural University,  
Bangladesh

### Article info

Received: 21 August 2024

Accepted: 20 January 2025

Published: 28 January 2025

### Keywords

*Allium sativum*, Albumin,  
Cholestasis, Cirrhosis, Liver, UDCA

### ABSTRACT

Cholestasis causes liver cirrhosis due to chronic total obstruction, in which accumulated bile acids induce liver inflammation and fibrosis. Inflammatory conditions are associated with hypoalbuminemia, and changes in albumin levels indicate the patient's clinical condition. *Allium sativum* has anti-inflammatory, antioxidant, and antifibrotic effects against various diseases. Further, ursodeoxycholic acid (UDCA) is one of the few available therapies for cirrhosis. Thus, this study aimed to assess the combination of *A. sativum* and UDCA as standard therapy in preventing liver cirrhosis and cholestasis. The current study was carried out with 35 male Sprague Dawley rats, which were randomly assigned into healthy, negative, and positive control groups, and three treatments of UDCA and graded doses of *A. sativum* extract. Biliary duct ligation was used for inducing cholestasis, and the treatment was given for 21 days. Liver cirrhosis was assessed based on Laennec grade by histopathological examination. Albumin levels are measured by examining blood serum. The combination of UDCA and *A. sativum* extract significantly reduced the degree of liver fibrosis and increased albumin levels in mice with cholestasis ( $p < 0.05$ ). There was no difference in the degree of liver fibrosis between the graded doses of *A. sativum*. Albumin levels were significantly correlated with the degree of liver fibrosis ( $p < 0.05$ ). In conclusion, the data suggest that *A. sativum* administration can be combined with UDCA to increase the hepatoprotective effect against cholestasis in rats.

### INTRODUCTION

Cholestasis is a stagnation or a marked reduction in bile secretion and flow from the liver. The accumulation of bile acids that occurs due to obstruction in their flow induces liver injury through an inflammatory response from hepatocytes [1]. Activation of nuclear factor- $\kappa$ B (NF- $\kappa$ B) mediates proinflammatory mediators such as tumor necrosis factor- $\alpha$  (TNF- $\alpha$ ) and interleukin 6 (IL-6) leading to hepatocyte apoptosis, hepatic stellate cells (HSC) and Kupffer cells activation in mouse models [2,3]. This condition will activate apoptotic signals through the caspase cascade, causing hepatocyte damage, degeneration, necrosis, and replacement of liver parenchyma by fibrotic tissue and regenerative nodules, as well as loss of liver function, which triggers fibrosis and ultimately leads to cirrhosis [4].

Patients with cirrhosis have impaired hepatocellular function and decreased albumin synthesis [5]. Inflammation increases capillary permeability and serum albumin release, causing expansion of the interstitial space and increasing the albumin volume of distribution. It also causes a shortening of the half-life of albumin and a decrease in the total mass of albumin [5]. Thus, hypoalbuminemia reflects an inflammatory state, which interferes with an adequate response to chronic inflammatory disease, surgery,



Copyright: © by the authors. This article is an open access article distributed under the terms and conditions of the [Creative Commons Attribution 4.0 \(CC BY 4.0\) International license](https://creativecommons.org/licenses/by/4.0/).

and chemotherapy and is associated with morbidity and mortality [6]. Albumin has been shown as a major prognostic factor, a predictor of mortality, and a component of the Child-Pugh-Turcotte score, the most frequently used prognostic scoring for cirrhosis [6].

Ursodeoxycholic acid (UDCA) is one of the few available therapies for cirrhosis. Administration of UDCA increases the amount of non-toxic hydrophilic bile acids in the liver and functions as a choleric agent, immunomodulatory, and protective agent for the hepatobiliary system [7]. Although UDCA can protect the liver from damage caused by bile acids, several further studies on UDCA show that 35-40% of people with chronic liver disease do not respond to UDCA administration and have a poor prognosis [8,9]. Only a small number of patients (<10% of the total) have gallstone disease that can be treated with UDCA, and this therapy cannot prevent the recurrence of gallstones [8,9]. Thus, further research is needed and encourages research to look for alternatives that can help increase the efficacy of UDCA.

*Allium sativum*, named garlic, has been used for a long time as a traditional medicine to reduce the risk of cardiovascular disease, aging, cancer, and diabetes. *A. sativum* has been shown to have an effect as a cytokine modulator, where its administration can inhibit the transcription factor NF- $\kappa$ B and proinflammatory cytokines such as TNF- $\alpha$ , transforming growth factor-beta 1 (TGF- $\beta$ 1), IL-1 $\beta$ , IL-6, monocyte chemoattractant protein-1 (MCP-1), matrix metalloproteinase 13 (MMP13) and IL-12 (p70) [10]. *A. sativum* also has an antioxidant effect, obtained through the catalytic effect of hydroxyl radical compounds and hydrogen peroxide into non-oxidative compounds, and it can prevent microsomal lipid peroxidation. Research shows that *A. sativum* extract (ASE) can prevent liver fibrosis by reducing myofibroblasts through modulating HSC activation mechanisms, remodeling the extracellular matrix (ECM) by increasing its degradation, and regenerating liver tissue and function through the formation of hepatocytes [11]. Considering the need for supplementation that can help to improve the hepatoprotective mechanism of UDCA, this study aimed to assess the combination of UDCA and ASE in preventing liver cirrhosis and decreasing albumin levels in cholestatic rats.

## MATERIALS AND METHODS

### Animal study

This study is approved for animal care, management, and experimental procedures by the Medical Research and Ethics Committee at Diponegoro University (109/EC-H/KEPK/FK-UNDIP/IX/2023). Thirty-six healthy male Sprague Dawley rats aged 2 months and weighing 150-200 g were included with no anatomical anomaly or damage to the liver. All of the rats were caged individually and acclimated for 7 days with a standard diet and drink. Surgery and intervention procedure allocation were assigned to each rat randomly using a randomized set of numbers. Cholestasis was induced using the bile duct ligation (BDL) technique involving a laparotomy procedure. 18 mg of cefotaxime (Indofarma, Jakarta, Indonesia) was given as a prophylaxis antibiotic, and 0.5 ml ketamine hydrochloride (Dexa Medica, Cikarang, Indonesia) as an anesthetic via intramuscular injections. Under sterile conditions, a midline laparotomy was performed, and the common bile duct was ligated with a 4-0 silk (DemeTECH, Miami Lakes, FL, USA). Sham-operated rats underwent the same surgical procedure except for BDL. Seven mg of oral Ibuprofen (Pharos, Semarang, Indonesia) was given every 8 h for 3 days to alleviate postoperative pain.

The rats were randomly assigned into 6 groups including sham, BDL, BDL+UDCA, BDL+UDCA+3.6mg ASE, BDL+UDCA+7.2mg ASE, and BDL+UDCA+14.4mg ASE, with each group include 6 rats. Standard diet and drink were given by the same pattern. UDCA (Dexa Medica, Cikarang, Indonesia) powder was administered orally at a dose of 13.5 mg /day based on conversion from the therapeutic dose used in humans [12]. ASE was extracted from garlic (Materia Medica, Batu, Indonesia) using the maceration method with 70% ethanol solution and administered orally based on the allocated treatment [13]. All treatments were given continuously by the laboratory caretaker for 21 days.

### Biochemical and histopathological analysis

Blood from the orbital vein of research animals was taken to check albumin levels on the 22<sup>nd</sup> day. The rats were then euthanized using ketamine hydrochloride (Dexa Medica, Cikarang, Indonesia). The liver tissue was taken and soaked in 10% formalin. The paraffin blocks were cut and stained using Masson's trichrome (MT). MT staining is commonly used to examine the degree of liver cirrhosis because MT staining provides a better illustration of early or late-stage cirrhosis compared to Hematoxylin-Eosin (HE) staining. The degree of liver cirrhosis will be determined using Laennec's scoring system by an independent pathologist. This system divides the degree of fibrosis and cirrhosis into grade 0 (no fibrosis), grade 1 (minimal fibrosis), grade 2 (mild fibrosis), grade 3 (moderate fibrosis), grade 4A (cirrhosis, mild definite or probable), 4B (moderate cirrhosis), and 4C (severe cirrhosis).

### Statistical analysis

Statistical analysis was performed using the IBM SPSS® 27.0 (New York, Manhattan). Data were expressed as means  $\pm$  SD. The normality test was conducted using the Shapiro-Wilk test. Statistical comparisons were conducted using the Kruskal Wallis and Mann-Whitney test for cirrhosis degree analysis, while one-way ANOVA and Post Hoc were used for albumin level analysis. A Spearman's correlation test was used to assess the correlation between the degree of cirrhosis and albumin level. A p-value of < 0.05 was considered significant.

## RESULTS

All rats (n = 36) received the allocated treatment completely until termination and were included in the final analysis. The subject's pre- and post-intervention weight showed a comparable body weight between the groups.

### Effect of UDCA and *A. sativum* extract on liver cirrhosis in cholestatic rats

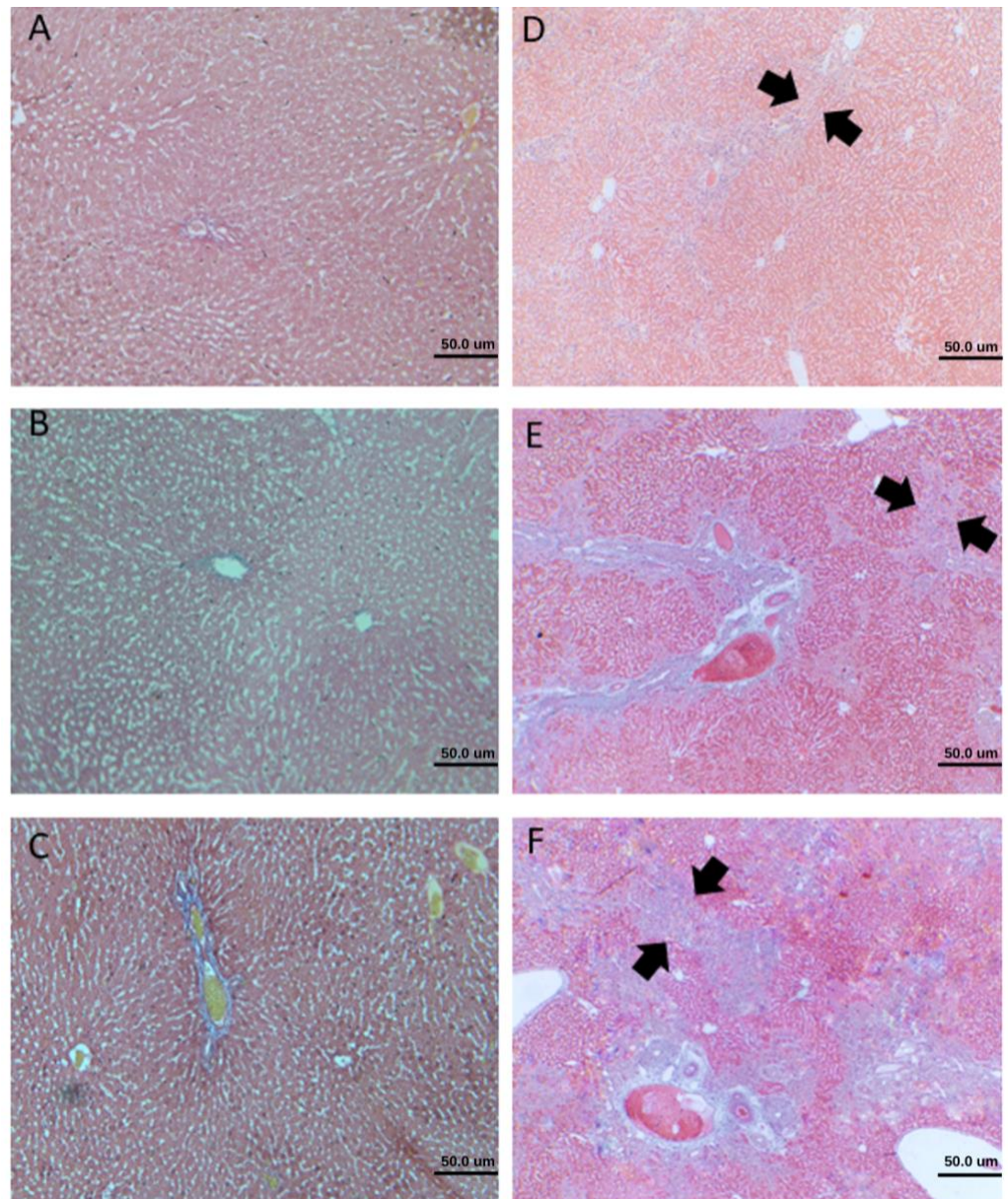
Table 1 shows that the results among Sham, BDL, and BDL+UDCA groups were significantly different, indicating that the BDL procedure results in a higher degree of cirrhosis, and administering UDCA reduced the severity. The difference between the BDL and intervention groups was significant, suggesting that the combination of UDCA and ASE decreased the degree of cirrhosis. However, data found that the results among BDL+UDCA+3.6mg ASE, BDL+UDCA+7.2mg ASE, and BDL+UDCA+14.4mg ASE were not comparable, suggesting that the graded dose doesn't have any significant effect on the degree of cirrhosis (Figure 1 and Table 2).



**Table 1.** Degree of liver cirrhosis between groups using the Kruskal-Wallis test.

Group	Degree of Cirrhosis						p <sup>ε</sup>
	0	1	2	3	4A	4B	
Sham	5	1	0	0	0	0	<0.001*
BDL	0	0	0	0	5	1	
BDL+UDCA	0	0	1	3	2	0	
BDL+UDCA+ 3.6mg ASE	0	2	2	2	0	0	
BDL+UDCA+ 7.2mg ASE	0	5	1	0	0	0	
BDL+UDCA+14.4mg ASE	0	6	0	0	0	0	

ASE, *Allium sativum* extract; ε, Kruskal-Wallis test; \* Significant (p < 0.05)



**Figure 1.** Microscopic evaluation of liver cirrhosis degree with 40x magnification. A) grade 0 (no fibrosis); B) grade 1 (minimal fibrosis); C) grade 2 (mild fibrosis); D) grade 3 (moderate fibrosis); E) grade 4A (cirrhosis, mild definite or probable); F) 4B (moderate cirrhosis); The appearance of septa (arrowhead).

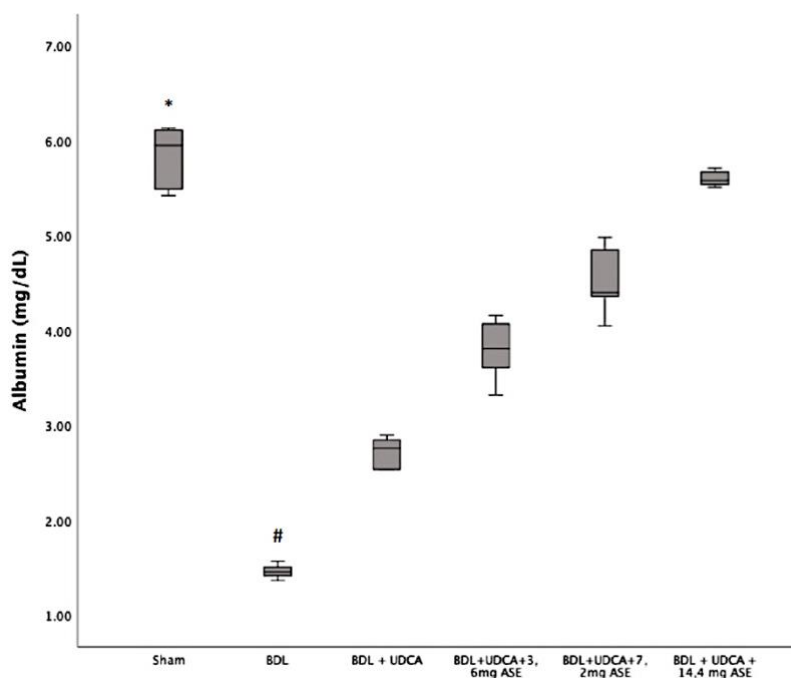
**Table 2.** Degree of liver cirrhosis using Mann Witney test.

Group	BDL	BDL + UDCA	BDL + UDCA + 3.6 mg ASE	BDL + UDCA + 7.2 mg ASE	BDL + UDCA + 14.4 mg ASE
Sham	0.002*	-	-	-	-
BDL	-	0.041*	0.002*	0.002*	0.002*
BDL+UDCA	-	-	0.045*	0.002*	0.002*
BDL+UDCA+ 3.6mg ASE	-	-	-	0.071	0.065
BDL+UDCA+ 7.2mg ASE	-	-	-	-	0.699

\* Significant (p < 0.05)

### Effect of UDCA and *A. sativum* extract on albumin level in cholestatic rats

A comparison of albumin levels among the groups showed a significant difference, indicating that the BDL group had significantly decreased albumin levels and experienced higher liver injury. UDCA and ASE administration significantly improved the albumin levels in cholestatic rats, compared to administrating only UDCA (Figure 2).



**Figure 2.** Effect of UDCA and *A. sativum* extract on albumin level. Results are expressed as median, interquartile range, maximum, and minimum values. Designations: p < 0.05 vs \* BDL; # BDL vs others.

### Correlation between degree of liver cirrhosis and albumin level in cholestatic rats

The correlation of the degree of liver cirrhosis and albumin levels using Spearman's correlation test shows a p-value < 0.001 and a correlation coefficient of -0.925, indicating that the degree of liver cirrhosis is correlated with albumin levels, with the direction and strength of the correlation being very strongly negative (Table 3).

**Table 3.** Correlation between degree of liver cirrhosis and albumin level.

Degree of Liver Cirrhosis	Albumin		P	r
	Mean $\pm$ SD	Median (min – max)		
0	5.82 $\pm$ 0.34	5.95 (5.42 – 6.13)	<0.001*	-0.925
1	4.98 $\pm$ 0.65	5.20 (4.05 – 5.71)		
2	3.58 $\pm$ 0.52	3.71 (2.85 – 4.05)		
3	2.96 $\pm$ 0.34	2.90 (1.37 – 3.32)		
4A	1.77 $\pm$ 0.52	1.51 (1.42 – 2.54)		
4B	1.37	1.37		

\* Significant ( $p < 0.05$ )

## DISCUSSION

The administration of UDCA and ASE in this study proved to improve the degree of liver cirrhosis, as shown by the significant difference between the treatment and negative control groups. The combination also resulted in a better degree of liver cirrhosis than UDCA alone, indicating the beneficial role of combining ASE with UDCA. However, a comparison of the treatment groups showed that there were no significant differences between the 3 graded doses of ASE used, indicating that there was no dose-dependent effect of this combination on the degree of cirrhosis. The smallest dose of ASE at 3.6 mg produced similar levels of improvement in the degree of liver cirrhosis if compared with a larger dose.

According to a study, ASE has an anti-fibrotic effect due to its antioxidant property, which was confirmed in liver cirrhosis induced by carbon tetrachloride (CCl<sub>4</sub>) [14]. The mechanisms underlying liver cirrhosis focus on increased synthesis of the extracellular matrix or decreased degradation, where excessive deposition of this matrix will alter the structure and function of the organ [14]. The organosulfur components of garlic are known to have chemical properties that work by competitive inhibition of tissue transglutaminase, hence the expression and transduction of enzyme genes involved in the progression of cirrhosis will be reduced [15]. Histopathology studies also confirmed that *A. sativum* has the ability to reduce myofibroblasts through modulation of HSC activation, initiate remodeling of the extracellular matrix through increased degradation, and enhance regeneration of liver tissue through the formation of hepatocytes [16].

Albumin level has previously been proven as a marker of liver damage. Analysis of the treatment group showed that administering graded doses of UDCA and ASE resulted in improved albumin levels, with the administration of ASE at a dose of 14.4 mg found to increase albumin levels to reach normal levels. This is in line with the finding of a hepatoprotective effect of ASE shown by the increased albumin levels in livers experiencing oxidative stress due to cisplatin [17]. In addition, in vitro data indicated that this extract had strong antioxidant protection, which supports the notion that the ASE has a significant role in preventing liver damage [18]. Panyod *et al.* confirmed that the use of allicin derived from ASE can reduce liver damage caused by alcoholic fatty liver disease in rat models. Activated Kupffer cells release reactive oxygen species (ROS) and pro-inflammatory cytokines such as TNF- $\alpha$ , IL-6, and IL-1 $\beta$ , which were reduced by ASE administration [19].

This research found a correlation between the degree of cirrhosis and albumin levels, where a lower degree of cirrhosis was correlated with higher albumin levels and vice versa. Albumin and bilirubin levels, as part of the albumin-bilirubin (ALBI) score, have been correlated with the degree of cirrhosis [20]. The use of this score is based on the role of bilirubin and albumin as markers of liver function. In addition, among other

markers from blood tests, albumin and platelets are the components that correlate most strongly with the degree of cirrhosis, where albumin levels will decrease as cirrhosis progresses [21]. Thus, decreasing albumin levels are associated with increasing liver damage, characterized by increasingly advanced degrees of liver cirrhosis. Overall, UDCA and ASE significantly improved the degree of liver cirrhosis and albumin levels in cholestatic rats. The efficacy of UDCA and ASE increased using the greater dose of *A. sativum*. There is also a correlation between the decrease of cirrhosis degree with the increase of albumin levels in cholestatic rats.

This study's advantages are assessing the success of choledochal duct ligation in inducing cholestasis and assessing the outcome of the intervention with direct visualization through histopathological examination of liver tissue biopsy samples. However, there are several limitations. This research was carried out in vivo using a test animal model, so there is a possibility that the results would have different effects if carried out on human subjects. This study only assessed the outcome of the intervention on day 22, so during the 21 days of intervention, there was no assessment of the progression of the therapeutic effects resulting from UDCA and ASE. We didn't measure the laboratory markers of liver fibrosis and/or cirrhosis, hence further studies could evaluate the markers to help confirm the process. Finally, the current study didn't conduct a phytochemical analysis to confirm the compositions of chemicals in the extract, with further studies needed to evaluate the components involved.

#### ACKNOWLEDGMENTS

None.

#### AUTHOR CONTRIBUTIONS

PA, NS, and SP conceptualized the study, performed the experiment, analyzed data, and interpreted the results. NM and TN contributed suggestions and checked the interpretation of the data. All authors reviewed and approved the final version of the manuscript.

#### CONFLICTS OF INTEREST

There is no conflict of interest among the authors.

#### REFERENCES

- [1] Chen H, Ling W, et al. Jaundice revisited: recent advances in the diagnosis and treatment of inherited cholestatic liver diseases. *J Biomed Sci.* 2018;25:75.
- [2] Zhou WC, Zhang QB, et al. Pathogenesis of liver cirrhosis. *World J Gastroenterol.* 2014;20:7312–24.
- [3] Weiskirchen R, Tacke F. Cellular and molecular functions of hepatic stellate cells in inflammatory responses and liver immunology. *Hepatobiliary Surg Nutr.* 2014;3:344–63.
- [4] Puche JE, Saiman Y, et al. Hepatic stellate cells and liver fibrosis. *Compr Physiol.* 2013;3:1473–92.
- [5] Soeters PB, Wolfe RR, et al. Hypoalbuminemia: Pathogenesis and Clinical Significance. *J Parenter Enter Nutr.* 2019;43:181–93.
- [6] Carvalho JR, Machado VM. New Insights About Albumin and Liver Disease. *Ann Hepatol.* 2018;17:547-560.
- [7] Onofrio FQ, Hirschfield GM. The Pathophysiology of Cholestasis and Its Relevance to Clinical Practice. *Clin Liver Dis.* 2020;15:110–4.
- [8] Tsochatzis EA, Feudjo M, et al. Ursodeoxycholic acid improves bilirubin but not albumin in primary biliary cirrhosis: Further evidence for nonefficacy. *Biomed Res Int.* 2013;2013.

- [9] Guarino MPL, Cocca S, et al. Ursodeoxycholic acid therapy in gallbladder disease, a story not yet completed. *World J Gastroenterol.* 2013;19:5029–34.
- [10] You S, Nakanishi E, et al. Inhibitory effects and molecular mechanisms of garlic organosulfur compounds on the production of inflammatory mediators. *Mol Nutr Food Res.* 2013;57:2049–60.
- [11] D'Argenio G, Amoruso DC, et al. Garlic extract prevents CCl<sub>4</sub>-induced liver fibrosis in rats: The role of tissue transglutaminase. *Dig Liver Dis.* 2010;42:571-7.
- [12] Razori MV, Maidagan PM, et al. Anticholestatic mechanisms of ursodeoxycholic acid in lipopolysaccharide-induced cholestasis. *Biochem Pharmacol.* 2019;168:48-56.
- [13] Abubakar AR, Haque M. Preparation of Medicinal Plants: Basic Extraction and Fractionation Procedures for Experimental Purposes. *J Pharm Bioallied Sci.* 2020;12:1-10.
- [14] Qiu JF, Zhang ZQ, et al. Cystamine ameliorates liver fibrosis induced by carbon tetrachloride via inhibition of tissue transglutaminase. *World J Gastroenterol.* 2007;13:4328-32.
- [15] Ansary J, Forbes-Hernández TY, et al. Potential Health Benefit of Garlic Based on Human Intervention Studies: A Brief Overview. *Antioxidants (Basel).* 2020;9:619.
- [16] D'Argenio G, Mazzone G, et al. Garlic extract attenuating rat liver fibrosis by inhibiting TGF- $\beta$ 1. *Clin Nutr.* 2013;32:252-8.
- [17] Nasr AY. Protective effect of aged garlic extract against the oxidative stress induced by cisplatin on blood cells parameters and hepatic antioxidant enzymes in rats. *Toxicol Rep.* 2014;16:682-691.
- [18] Almatroodi SA, Anwar S, et al. Hepatoprotective Effects of Garlic Extract against Carbon Tetrachloride (CCl<sub>4</sub>)-Induced Liver Injury via Modulation of Antioxidant, Anti-Inflammatory Activities and Hepatocyte Architecture. *Applied Sciences.* 2020;10:1-22.
- [19] Panyod S, Wu WK, et al. Diet Supplementation with Allicin Protects against Alcoholic Fatty Liver Disease in Mice by Improving Anti-inflammation and Antioxidative Functions. *J Agric Food Chem.* 2016;64:7104-7113.
- [20] Fujita K, Oura K, et al. Albumin-bilirubin score indicates liver fibrosis staging and prognosis in patients with chronic hepatitis C. *Hepato Res.* 2019;49:731-742.
- [21] Fujita K, Yamasaki K, et al. Albumin platelet product as a novel score for liver fibrosis stage and prognosis. *Sci Rep.* 2021;11:5345.