



## Prophylactic effect of vitamin E and coriander (*Coriandrum sativum*) seed extract against lead toxicity in liver of Swiss albino mice

Md. Anwar Jahid<sup>1</sup>, Mohammad Zahirul Islam Khan<sup>2</sup> and Mohammad Rafiqul Islam<sup>2\*</sup>

<sup>1</sup>Department of Anatomy & Histology, Faculty of Animal Science and Veterinary Medicine, Patuakhali Science and Technology University, Khanpura, Babugonj, Barishal-8210, Bangladesh.

<sup>2</sup>Department of Anatomy & Histology, Bangladesh Agricultural University, Mymensingh-2202, Bangladesh.

\*Corresponding author: Dr. Mohammad Rafiqul Islam, Department of Anatomy & Histology, Bangladesh Agricultural University, Mymensingh-2202, Bangladesh, E-mail: [rafiqul.islam@bau.edu.bd](mailto:rafiqul.islam@bau.edu.bd)

**Academic Editor:** Dr. Md. Abdul Hannan, Dongguk University, South Korea.

Received: 17 June 2020; Accepted: 02 August 2020; Published: 10 August 2020.

**ABSTRACT:** Lead is the most abundant toxic metal in the environment that causes serious health hazards in animals and humans. In this study, the prophylactic effects of vitamin E and coriander (*Coriandrum sativum* L.) seed extract on lead-induced liver damage in Swiss albino mice were investigated by gross and histological studies. At first, mice were intoxicated with a particular dose of lead acetate for 42 days. After intoxication, mice were divided into three groups for treatment purpose. The first and second groups of mice were treated with vitamin E and coriander extract respectively. Both vitamin E and coriander extract were given to the third group of mice. Treatment was done for 42 days. In this study, lead acetate was found to cause nodular lesion and congestion in the central vein in liver. Vitamin E was found effective in the treatment of congestion in the central vein of liver but ineffective in the treatment of the nodular lesion. The nodular lesion was found in liver even after vitamin E treatment. The liver was found normal in the coriander extract-treated group as well as combined vitamin E and coriander extract-treated group. There was no nodular lesion as well as congestion in the central vein of liver in these two groups. The present findings revealed that lead has detrimental effects on the liver of mice. Treatment with coriander extract was found more effective than the treatment with vitamin E in lead intoxicated mice. The combined action of vitamin E and coriander extract is more effective than their individual action. The present investigation may serve as baseline data about the adverse effects of lead toxicity and efficacy of vitamin E and coriander extract against lead toxicity.

**KEYWORDS:** Lead, hepatotoxicity, vitamin E, coriander, mice.

### INTRODUCTION

Lead is believed to be the most available occupational and environmental toxicant that has serious potential health hazards to animals and humans. Livestock is affected by lead toxicity in Bangladesh [1]. Soft tissues like liver, kidney, brain, ovary, and testis are affected seriously. Lead has a wide range of toxic biochemical and histological impacts when it deposits in these soft organs. In our previous study, we found lead acetate causes morphological deformities of seminiferous tubules and irregular arrangement of spermatogenic cells in the seminiferous tubules of mice testis [2]. Lead, as a

toxicant, is very harmful to the liver and its associated functions. The liver, responsible for maintaining the body's metabolic homeostasis has been considered as the target organ for the toxic effects of lead [3]. Considerable alterations induced by lead intoxication were seen in the nuclei of the hepatocytes [4, 5]. Nuclear polymorphism is seen in hepatic dysplasia and carcinomatous lesion due to lead toxicity [6].

Many antioxidants including vitamin C [7] and vitamin E [8] have been used to prevent the lead toxicity and to reduce oxidative stress in tissues. Vitamins are ideal antioxidants to increase tissue protection from oxidative stress due to their easy, effective, and safe dietary administration in a large range of concentrations [9].

Vitamin E exerts its action as a free radical scavenger, scavenging superoxide, hydrogen peroxide, and hydroxyl radicals [10]. Vitamin E is believed to be an ideal antioxidant to increase tissue protection from oxidative stress [11].

The coriander seed is one of the most popular spices in the world. Coriander is also popular for its antioxidant properties. Properties of coriander as an antioxidant could be directly linked to both the scavenging function against reactive oxygen species and the elevation of antioxidant makeup. Coriander helps to remove harmful mineral residue such as lead and mercury from the body through the feces and urine. It also increases chloramphenicol acetyltransferase and salicylate dioxygenase functions, and glutathione content and decreases lipid peroxidation level in lead-induced mice tissues. It has been reported that the activities of antioxidant enzymes (glutathione peroxidase, catalase) increased, and the formation of lipid peroxides reduced in rats treated by coriander extracts [12].

The present study was designed to investigate the effects of lead toxicity on the liver of Swiss albino mice and possible prophylactic effects produced by vitamin E and extract of coriander seeds supplementation.

## MATERIALS AND METHODS

### Animals

The study was conducted in the Department of Anatomy and Histology, Faculty of Veterinary Science, Bangladesh Agricultural University, Mymensingh-2202. The experimental Swiss albino mice (male) were collected from Department of Pharmacy, Jahangirnagar University, Dhaka. Collected mice were 6 weeks of age and about 25-28 grams at the time of collection. All mice were raised under confinement as an intensive system. Mice were kept in cages at room temperature. Water and feed were supplied *ad libitum* to the mice. All experimental protocols were approved by the Animal Welfare and Ethical Committee, Faculty of Veterinary Science, Bangladesh Agricultural University; Order no. AWEEC/BAU/2019 (4), Date: 12.03.2019.

### Chemicals

Lead (II) acetate trihydrate and Vitamin E were purchased from Merck (Darmstadt, Germany). Aqueous coriander extract was prepared in the Department of Pharmacology, Faculty of Veterinary Science, Bangladesh Agricultural University, Mymensingh. Coriander extract was prepared according to the procedure of previous research [13].

### Treatment

Mice were divided into different groups according to the experimental design. At first, there were two groups- Group A: Control group (10 mice) and Group B: Lead intoxicated group (25 mice). Only feed and normal water were given to the control group. The lead intoxicated group was treated with 60 mg lead acetate per kg body weight every day orally for 6 weeks. After six weeks samples were collected from 5 mice of the control group and 5 mice of the intoxicated group. Remaining 5 mice of the control group were kept as a control for the next 6 weeks. Five mice of the intoxicated group were further intoxicated for the next 6 weeks. The other 15 mice of the intoxicated group were divided into three groups (C, D, and E) each having 5 mice. Group C was treated with 150 mg vitamin E (diluted in soya oil) per kg body weight every day orally for 6 weeks. Group D was treated with 300 mg coriander extract (diluted in distilled water) per kg body weight every day orally for 6 weeks. Group E was treated with both vitamin E (150 mg per kg body weight) and coriander extract (300 mg per kg body weight) in every day orally for 6 weeks. The doses of lead acetate, vitamin E, and coriander seed extract were selected on the basis of previous studies [13, 14]. After completion of the experiment, the liver was collected from all the mice of different groups.

### Gross and histology

In the gross study, parameters such as color, weight, and length were taken into consideration. All kinds of abnormalities were also observed. The color of liver was compared with the liver of control group by eye observation. Weight was measured in gram by electronic balance. The length of liver of different groups was measured by a graded scale. The unit of length measurement was millimeter.

After gross observation, samples were preserved in 10% formalin and Bouin's fluid. After proper fixation, samples were processed for histological study. H & E staining protocol was applied. A detailed histological study was done using a light microscope.

### Photomicrographs

Photographs for the present study were taken according to a previous study which was performed in the same laboratory [15]. Necessary photomicrographs were taken with Olympus BX 51 photographic light microscope and placed for better illustration of the result.

## Data analysis

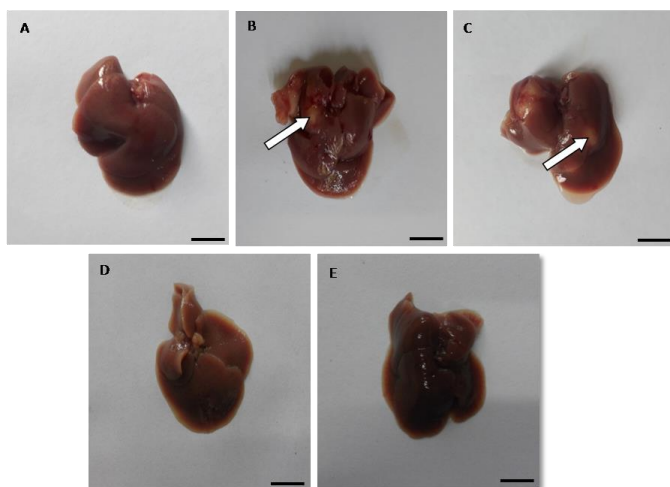
All the collected data were then analyzed using Statistical Package for the Social Sciences (SPSS; version 22.0) software and disrobe the results in tabular form. The chi-squared test was used for the analytical assessment. The differences were considered statistically significant when the p values were less than 0.05.

## RESULTS

Prophylactic effects of vitamin E and coriander (*Coriandrum sativum* L.) seed extract on lead-induced liver damage in Swiss albino mice were investigated in this study. Results of different parameters studied in the experiment have been presented under two subheadings. The studied results have been presented in different figures for better illustration.

### Gross observation

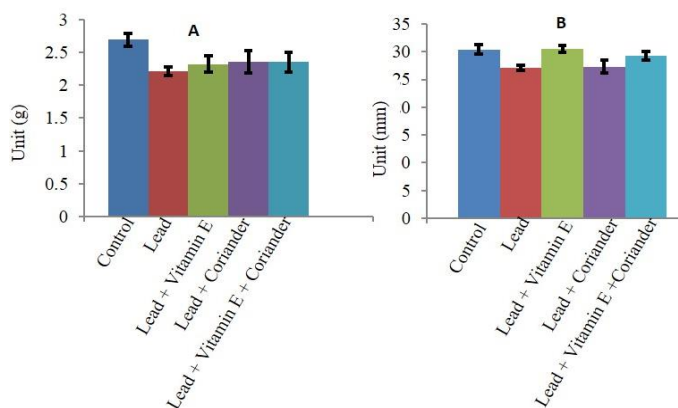
The liver of control group was reddish (Figure 1A). The liver was also reddish in the intoxicated group (Figure 1B) and treatment groups (Figure 1 C-E). But nodular lesion was found in the intoxicated group (Figure 1B). The nodular lesion was also found in the vitamin E treated group (Figure 1C). In case of the coriander extract-treated group, the nodular lesion was not found (Figure 1D). On the other hand, the appearance of liver was found normal in combined vitamin E and coriander extract-treated group (Figure 1E). The nodular lesion was not observed in this group.



**Figure 1.** Gross observation of liver in mice. Normal appearance of liver was found in the control group (A). Nodular lesion (white arrow) was found in the lead intoxicated group (B). Nodular lesion (white arrow) was also found in the vitamin E treated group (C). Normal appearance of liver in coriander extract-treated group (D), and vitamin E and coriander extract (combined) treated group (E). Scale bar = 1 cm.

The mean weights of liver in the control group, intoxicated group, vitamin E-treated group, coriander extract-treated group, and combined vitamin E and coriander extract-treated group were  $2.69 \pm 0.10$ ,  $2.21 \pm 0.06$ ,  $2.32 \pm 0.12$ ,  $2.36 \pm 0.17$  and  $2.35 \pm 0.15$  g, respectively (Figure 2A).

The mean lengths of liver in the control group, intoxicated group, vitamin E-treated group, coriander extract-treated group, and combined vitamin E and coriander extract-treated group were  $30.43 \pm 0.88$ ,  $27.14 \pm 0.46$ ,  $30.50 \pm 0.59$ ,  $27.29 \pm 1.19$  and  $29.29 \pm 0.81$  mm, respectively (Figure 2 B).

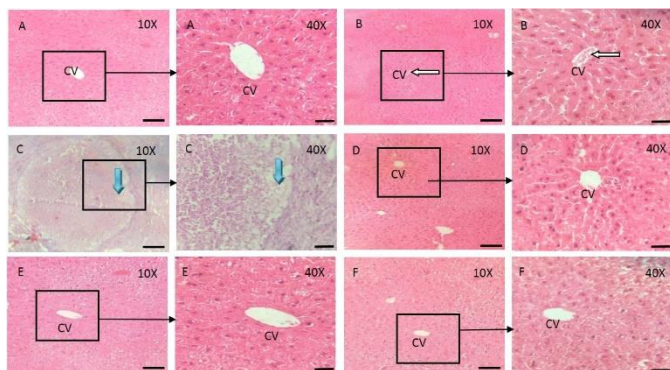


**Figure 2.** Weight (A) and length (B) of liver of mice in different groups (Mean  $\pm$  standard error).

### Histological observation

In the present study, the liver was found with normal histological architecture in the control group (Figure 3A). In the lead intoxicated group, congestion in central vein and nodule with fibrous covering were found in some sections (Figure 3 B-C). The appearance of liver was found normal in vitamin E treated group, coriander extract-treated group, and combined vitamin E and coriander extract-treated group. Congestion in the central vein and nodular lesion were not observed in these groups (Figure 3 D-F).





**Figure 3.** (A-F): Histological observation of liver in mice (H&E). Normal appearance of liver was found in the control group (A, 10X and 40X). In the lead intoxicated group, congestion in the central vein (white arrow) was found in some sections (B, 10X and 40X). In addition, nodular lesion (blue arrow) was also found in some sections of this group (C, 10X and 40X). Appearance of liver was found normal in vitamin E treated group (D, 10X and 40X), coriander extract-treated group (E, 10X and 40X), and vitamin E and coriander extract (combined) treated group (F, 10X and 40X). CV= Central vein. Scale bar: 5  $\mu$ m (10X) and 1  $\mu$ m (40X).

## DISCUSSION

In the present study, the prophylactic effects of vitamin E and coriander (*Coriandrum sativum* L.) extract on lead-induced hepatic damage in Swiss albino mice were investigated in detail by gross and histological studies.

Livers of all groups were found reddish. The nodular lesion was found in the lead intoxicated group of mice. Regarding nodular lesion, literature is not available. However, some researchers reported regarding carcinomatous lesion which is partially consistent with my findings [6]. They reported that nuclear polymorphism is seen in hepatic dysplasia and carcinomatous lesion due to lead toxicity. The actual mechanism of nodule formation is unknown. But this may be due to increased cellular activity and nuclear interruption in the mechanism of lead detoxification.

Vitamin E was found unable to reduce the nodular lesions in the liver as the nodular lesion was also found in the vitamin E-treated group in the present study. It indicates that the properties of vitamin E as an antioxidant are not effective to reduce the nodular lesion, although some investigators described the role of vitamin E as an antioxidant [9]. The nodular lesion was not observed in the coriander extract-treated group in the present study. It indicates that the properties of coriander extract as an antioxidant can prevent the formation of nodular lesion in the liver. This report is supported by the findings of previous researchers [13]. They suggested that aqueous and ethanolic extracts of *Coriandrum sativum* can prevent or slow down the oxidative damage induced by lead in mice. The nodular lesion was not observed in vitamin E and coriander extract-treated group. This may be due to

the fact of the combined actions of vitamin E and coriander extract.

The mean length and mean weight of liver in the lead intoxicated group were reduced in comparison to the control group. This is partially supported by the other research findings which found decrease growth rate in rats when fed with lead [16]. More probably, decreased weight of liver is due to reduced body weight.

In the lead intoxicated group, congestion was found in the central vein in some of the sections in the present study. In addition, nodule with fibrous covering was found in this group. Present findings are partially consistent with the previous report of carcinomatous lesion in which lead has been classified as a possible human carcinogen on the basis of sufficient evidence for carcinogenicity in experimental animals but inadequate evidence for carcinogenicity in humans [17].

Normal histology of liver was found in vitamin E treated group, coriander extract-treated group, and vitamin E and coriander extract (combined) treated group in the present study. There was no congestion in the central vein of liver in these groups. This may be due to the antioxidative actions of vitamin E and coriander extract. This is supported by the findings of other researchers. It has been reported that vitamin E is an ideal antioxidant to increase tissue protection from oxidative stress [11]. It has also been reported that vitamin E has an antioxidant function and other functions include enzymatic activities, gene expression, and neurological function [18].

## CONCLUSIONS

Lead is the most abundant toxic metal in the environment. The present findings revealed that lead has detrimental effects on the liver of mice. Lead was found to cause nodular lesion and congestion in the central vein in liver of mice. Vitamin E showed its antioxidative effects in the present study. Vitamin E was found effective against congestion in the central vein of liver but was ineffective to prevent the formation of nodular lesion in the liver. Treatment with coriander extract was found more effective than treatment with vitamin E in lead intoxicated mice. The gross and microscopic architecture of liver was found normal in this group. The gross and microscopic architecture of liver was also found normal in vitamin E and coriander extract (combined) treated group. The present investigation may serve as baseline data about the harmful effects of lead toxicity and efficacy of vitamin E and coriander extract against lead toxicity. Further research needs to be carried out to isolate and purify the active principle involved in the antioxidant activity of coriander seed.

## ACKNOWLEDGEMENT

The authors would like to express their gratitude to the Ministry of Science and Technology (MoST), Bangladesh for providing National Science and Technology (NST) fellowship for the year 2017-18 to conduct the research works (Grant number-1520/722) and sincerely acknowledge the support of the Department of Pharmacology, Bangladesh Agricultural University.

## AUTHOR CONTRIBUTIONS

MRI designed the experiment. MAJ performed the experiments, analyzed the data and wrote the draft. MRI and MZIK critically revised the manuscript.

## CONFLICTS OF INTEREST

Authors declared that they have no conflict of interest.

## REFERENCES

- [1] Forsyth JE, Weaver KL, Maher K, Islam MS, Raqib R, Rahman M, Fendorf S, Luby SP. Sources of blood lead exposure in rural Bangladesh. *Environmental Science & Technology*. 2019; 53(19): 11429-11436.
- [2] Islam MR, Jahid MA, Khan MZI, Islam MN. Prophylactic effects of vitamin E and coriander (*Coriandrum sativum*) extract on lead-induced testicular damage in Swiss albino mice. *J Adv Biotechnol Exp Ther*. 2019; 2(1):31-35.
- [3] Patra RC, Swarup D, Dwivedi SK. Antioxidant effects of alpha-tocopherol, ascorbic acid and L-methionine on lead induced oxidative stress to the liver, kidney and brain in rats. *Toxicology*. May 11, 2001; 162(2):81-88.
- [4] Piasek M, Kostial K, Bunarevic A. The effect of lead exposure on pathohistological changes in the liver and kidney in relation to age in rats. *Arh. Hig. Rada.Toksikol*. 1989; 40(1):15-21.
- [5] Jarrar BM, Mahmoud ZN. Histochemical demonstration of changes in the activity of hepatic phosphatases induced by experimental lead poisoning in male white rats (*Rattus norvegicus*). *Toxicol. Ind. Health*. 1999; 15:1-9.
- [6] Zusman I, Kozlenko M, Zimmer A. Nuclear polymorphism and nuclear size in precarcinomatous and carcinomatous lesions in rat colon and liver. *Cytometry*. 1991; 12(4): 302-307.
- [7] Hsu PC, MY Liu, CC Hsu, LY Chen, YL Guo. Effects of vitamin E and/or C on reactive oxygen species-related lead toxicity in the rat sperm. *Toxicology*. 1998; 128:169-179.
- [8] Patra RC, Rautray AK, Swarup D. Oxidative stress in lead and cadmium toxicity and its amelioration. *Veterinary Medicine International*. 2011; 1-9.
- [9] Janisch KM, Milde J, Schempp H, Elstner E. Vitamin C, Vitamin E and flavonoids. *Dev. Dphthal. mol*. 2005; 38:59-69.
- [10] Kartikeya M, Agarwal A, Sharma R. Oxidative stress and male infertility. *Indian J. Med. Res*. 2009; 129:357-367.
- [11] Flora G, Gupta D, Tiwari A. Toxicity of lead review with recent updates. *Inter. Toxicol*. 2012; 5(2):47- 58.
- [12] Chithra V, Leelamma S. *Coriandrum sativum* changes the levels of lipid peroxidase and activity of antioxidant enzymes in experimental animals. *Ind J Biochem Biophys*. 1999; 36:59-61.
- [13] Kansal L, Sharma A, Lodi S. Remedial effect of *Coriandrum sativum* (coriander) extracts on lead induced oxidative damage in soft tissues of Swiss albino mice. *Int J Pharm Pharm Sci*. 2012; 4 (3):729-736.
- [14] El-Tohami AA, Ali EK. Effect of vitamin E supplementation on testicular tissues of mice exposed to sub-chronic lead intoxication. *Trends in Medical Research*. 2014; 9: 33-43.
- [15] Jannat N, Sultana N, Jahan MR, Islam MR. Long term administration of gentamicin affects hemato-biochemical parameters and liver architecture of Swiss Albino Mice. *J Adv Biotechnol Exp Ther*. 2018; 1 (2):29-35.
- [16] Nabil IM, Eweis EA, el-Beltaqi HS, Abdel-Mobdy YE. Effect of lead acetate toxicity on experimental male albino rat. *Asian Pacific Journal of Tropical Biomedicine*. 2012; 41-46.
- [17] IARC (International Agency for Research on Cancer). Lead and compounds, inorganic. *IARC Monographs*. Lyon. 1987; 23(7).
- [18] Songthaveesin C, Saikhun J, Kitiyananta Y, Pavasuthipaisit K. Radioprotective effect of vitamin E on spermatogenesis in mice exposed to gamma-irradiation: a flow cytometric study. *Asian J. Androl*. 2004; 6:331-336.



This is an Open Access article distributed under the terms of the Creative Commons Attribution Non-Commercial License, which permits unrestricted non-commercial use, distribution, and reproduction in any medium, provided the original work is properly cited.